

Our experience with transradial approach for coronary angiography

Transradial yaklaşımla koroner anjiyografi deneyimimiz

Veli Vefalı, M.D., Uğur Arslan, M.D.

Department of Cardiology, Çankaya Hospital, Ankara

Objectives: Transradial approach (TRA) for coronary angiography has only become popular in our country in recent years. In this study, we evaluated radial and femoral angiographies performed at our center.

Study design: A total of 487 patients (351 males, 136 females) were scheduled for coronary angiography using TRA in 2007. Data regarding the procedure were compared with those of 500 patients (369 males, 131 females) who underwent coronary angiography via the transfemoral approach (TFA). All the procedures were performed by the same experienced cardiologist. Coronary angiography from the radial artery was performed after a positive Allen test and a careful physical examination of the access site. A 100-cm Optitorque radial catheter was mostly used to cannulate both right and left coronary arteries. Transfemoral catheterization was performed using 6 Fr diagnostic catheters, usually Judkins curve catheters.

Results: Procedural success rates were 96.5% (n=470) and 98.4% (n=492) in the TRA and TFA groups, respectively (p>0.05). The two groups were similar with respect to the procedural variables, except for the access time which was slightly higher in the TRA group (p<0.01). A higher incidence of coronary slow flow was detected in the TRA group (p<0.01). In 423 patients (90.0%), a single catheter was used for both selective right and left coronary angiography in the TRA group, resulting in a significantly lower number of catheter use (2.1±0.2 vs 3.2± 03; p<0.001). Only minor complications were seen during TRA, most commonly being pain and ecchymoses. In the TFA group, 27 patients (5.4%) developed hematoma at the access site, of more than 5 cm in diameter. Hospital stay was significantly shorter in the TRA group (2.1±0.4 hr vs 6.7±1.0 hr; p<0.001).

Conclusion: Transradial coronary angiography is a good alternative to TFA and can be performed safely and effectively in eligible patients.

Key words: Coronary angiography/methods; heart catheterization/methods; femoral artery; radial artery.

Amaç: Transradial yaklaşımla (TRY) koroner anjiyografi ülkemizde son yıllarda benimsenmeye başlamış bir tekniktir. Bu çalışmada, merkezimizde uygulanan radial ve femoral anjiyografiler değerlendirildi.

Çalışma planı: 2007 yılında toplam 487 hastada (351 erkek, 136 kadın) TRY ile koroner anjiyografi yapılması planlandı. İşlemlerle ilgili veriler, transfemoral yaklaşımla (TFY) koroner anjiyografi yapılan 500 hastanın (369 erkek, 131 kadın) verileriyle karşılaştırıldı. Tüm işlemler aynı tecrübeli kardiyolog tarafından yapıldı. Radial arter yoluyla koroner anjiyografi, hastada pozitif Allen testi ve giriş bölgesinin dikkatli fizik muayenesi ardından yapıldı. Sağ ve sol koroner arterlerin kanülasyonu olguların büyük kısmında aynı kateterle (100 cm'lik Optitorque radial kateteri) yapıldı. Transfemoral kateterizasyon için, genellikle Judkins kavisli kateter olmak üzere, 6 Fr tanısal kateterler kullanıldı.

Bulgular: İşleme ilişkin başarı oranı TRY grubunda %96.5 (n=470), TFY grubunda %98.4 (n=492) bulundu (p>0.05). İki grubun işlemlerle ilgili değişkenleri, TRY grubunda biraz daha uzun olan giriş zamanı dışında (p<0.01) benzer bulundu. Ayrıca, TRY grubunda daha yüksek oranda koroner yavaş akım görüldü (p<0.01). Transradial yaklaşımda selektif sağ ve sol koroner anjiyografinin hastaların büyük çoğunluğunda (n=423, %90) tek bir kateterle yapılması nedeniyle, bu grupta kullanılan kateter sayısı anlamlı derecede daha az idi (2.1±0.2 ve 3.2± 03; p<0.001). Transradial yaklaşımla, çoğu ağrı ve ekimoz şeklinde olan önemsiz komplikasyonlar görülürken, TFY grubunda 27 hastada (%5.4), giriş bölgesinde çapı 5 cm'yi aşan hematoma gelişti. Hastanede kalış süresi TRY grubunda anlamlı derecede daha kısa idi (2.1±0.4 saat ve 6.7±1.0 saat; p<0.001).

Sonuç: Transradial koroner anjiyografi TFY'ye iyi bir seçenektir ve uygun hastalarda güvenli ve etkili bir şekilde yapılabilir.

Anahtar sözcükler: Koroner anjiyografi/yöntem; kalp kateterizasyonu/yöntem; femoral arter; radial arter.

Received: January 5, 2008 Accepted: February 18, 2008

Correspondence: Dr. Uğur Arslan. Güvenlik Cad., No: 38/4, 06550 Aşağı Ayrancı, Ankara, Turkey.
Tel: +90 312 - 468 66 71 Fax: +90 312 - 212 90 12 e-mail: ugur.arslan@tkd.org.tr

Coronary angiography is used as the gold standard technique to diagnose coronary artery disease. Most commonly, it is performed by the transfemoral approach (TFA). In recent years, the transradial approach (TRA) has become popular in our country because of lower vascular complication rates and better patient comfort.^[1,2]

Although TRA presents some technical difficulties to interventional cardiologists, it has been demonstrated that, in experienced hands, it is as safe and effective as TFA for either diagnostic or therapeutic purposes.^[3-7] This approach has been used in our institute for five years, whereby a total of 1,762 patients and 209 patients underwent coronary angiography and percutaneous coronary interventions, respectively.

In this study, we evaluated radial and femoral angiographies performed at our center.

PATIENTS AND METHODS

A total of 487 patients (351 males, 136 females) who were scheduled for coronary angiography using TRA between January and December 2007 were included in the study. Data regarding the procedure were collected, including procedure time, access and radiation times, contrast volume, complications, and length of hospital stay. These variables were compared to those of 500 consecutive patients (369 males, 131 females) who were submitted to coronary angiography via TFA in the same period. Patients who had a history of coronary artery bypass operation and who underwent right heart catheterization were excluded from the study. All the procedures were performed by the same experienced cardiologist (VV) after obtaining informed consent from the patients.

Coronary angiography from the radial artery was performed after a positive Allen test. Besides, the eligibility of the patients for TRA was sought with careful physical examination of the access site. Patients with arteriovenous fistulas for hemodialysis on their right arms or those having a mobile radial artery on palpation were not considered to be eligible for TRA.

Angiographic procedures. Transradial approach was started with the patient lying down with the right wrist placed in a hyperextended position. After local anesthesia with prilocaine (Citanest, AstraZeneca), the radial artery was punctured using a 3.8-cm Seldinger arterial needle. Then, a 6 Fr valved introducer sheath (St. Jude Medical, Minnetonka, USA), 8.5 cm in length, was advanced over a 0.021 inch guidewire. Following

administration of 10 ml mixture of saline and 5,000 U heparin through the sheath, a coronary catheter was introduced over a 0.038 inch, 150 cm guidewire. A 100-cm Optitorque radial catheter (Terumo, Leuven, Belgium) was mostly used to cannulate both right and left coronary arteries (Fig. 1). In case of unsuccessful cannulation, either standard left or right Judkins catheters were used. The sheath was removed immediately after the procedure and an elastic band was used to stop bleeding. The patients were asked to stay for two hours, during which access site was frequently controlled and discharged if there was no problem.

Transfemoral catheterization was performed using 6 Fr diagnostic catheters, usually Judkins curve catheters. After the procedure, the 6 Fr sheath was removed immediately and hemostasis was achieved by digital pressure on the access site. Patients were asked to stay for six hours after the procedure and the access site was controlled frequently. They were discharged if no complication occurred.

Five minutes before each procedure, the patients were premedicated with intravenous 2-4 mg midazolam (Dormicum, Roche) for sedation and amnesia so that they would feel more comfortable for a subsequent coronary angiography when needed.

Access time was defined as the interval between local anesthetic injection and sheath introduction, and procedural time was defined as the interval between local anesthetic injection and completion of coronary angiography.

The severity of coronary lesions was determined visually. Coronary angiograms were evaluated by two experienced cardiologists and coronary artery disease (CAD) was defined as the presence of $\geq 50\%$ stenosis in at least one major coronary artery. The extent of

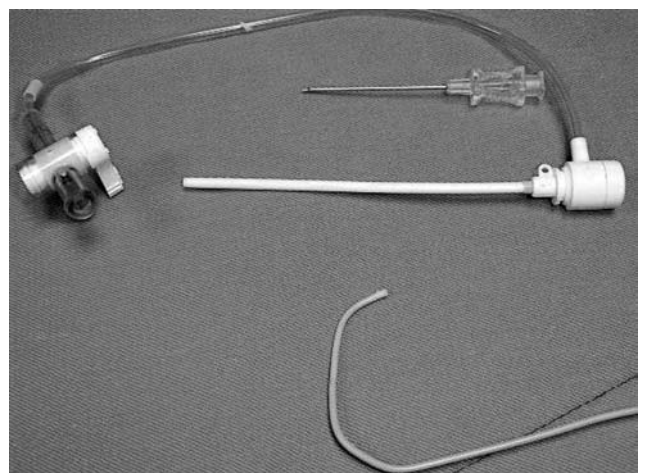


Figure 1. The needle, sheath, and Optitorque radial catheter.

CAD was defined according to the number of major coronary arteries affected, namely, one-vessel, two-vessel, and three-vessel disease. Coronary slow flow was also defined visually as slow dye progression in the coronary arteries during selective coronary angiography.

Statistical analysis. Analysis of the results was performed using the Statistical Package for Social Sciences, version 15.0 software for Windows. Continuous variables were expressed as mean \pm standard deviation, and categorical variables as percentages. Data were tested for normal distribution using the Kolmogorov-Smirnov test. Continuous variables of normal and non-normal distribution were compared with an independent t-test and Mann-Whitney U-test, respectively. Categorical variables were assessed using the chi-square test. Statistical significance was defined as a P value of less than 0.05.

RESULTS

Of 487 candidates, 470 patients (96.5%) were found to be eligible for TRA. In 17 patients, TRA could not be performed because of brachial and radial tortuosity (n=10), failure of access (n=6), or radial spasm (n=1).

Characteristics of all the patients are shown in Table 1. The two groups were similar with respect to the procedural variables, except for the access time which was slightly higher in the TRA group (p<0.01). Coronary angiography findings were also similar in the two groups, with the exception of a higher incidence of coronary slow flow in the TRA group (p<0.01, Table 1).

As a single catheter was used for coronary cannulation in a great majority of patients undergoing TRA, the mean catheter number used for TRA was significantly lower than that used in the TFA group (2.1 \pm 0.2 vs 3.2 \pm 0.3; p<0.001). Out of 470 patients, a single catheter was used for both selective right and left coronary angiography in 423 patients (90.0%), two catheters in 32 patients (6.8%), three catheters in nine patients (1.9%), and four catheters in six patients (1.3%). For those requiring ventriculography, a pigtail catheter was successfully used in 450 patients (95.7%) in the TRA group, and in 483 patients (96.6%) in the TFA group (p=0.8).

Only minor complications were seen during TRA, most commonly being pain and ecchymoses. In the TFA group, 27 patients (5.4%) developed hematoma at the access site, of more than 5 cm in diameter. None of these patients needed blood transfusion.

Hospital stay was also significantly lower in the TRA group (2.1 \pm 0.4 hours vs 6.7 \pm 1.0 hours; p<0.001).

DISCUSSION

Our results confirmed that TRA was at least as safe and effective as TFA, with the advantages of short hospital stay and lower complication rates. This approach has been used for several years in the world^[7-9] and has become popular in our country in recent years. However, technical difficulties and long learning curve limit the use of TRA by many interventional cardiologists.

The experience of the physician has been shown to play a major role in the procedural success.^[10] For

Table 1. Characteristics of patients submitted to coronary angiography by the transradial (TRA) or transfemoral (TFA) approach

	TRA (n=487)			TFA (n=500)			p
	n	%	Mean \pm SD	n	%	Mean \pm SD	
Age (years)			56 \pm 14			56 \pm 12	NS
Sex (males)	351	72.1		369	73.8		NS
Coronary artery lesions							
Normal coronary arteries	95	19.5		104	20.8		NS
1-vessel disease	117	24.0		122	24.4		NS
2-vessel disease	135	27.7		140	28.0		NS
3-vessel disease	100	20.5		102	20.4		NS
Left main coronary artery disease	23	4.7		24	4.8		NS
Coronary slow flow	37	7.6		8	1.6		<0.01
Procedure time (min)			10 \pm 2			9 \pm 3	NS
Access time (sec)			92 \pm 34			70 \pm 20	<0.01
Radiation time (sec)			128 \pm 33			135 \pm 30	NS
Contrast volume (mL)			110 \pm 24			108 \pm 22	NS
Success rate	470	96.5		492	98.4		NS

NS: Not significant.

the first time in our country, Yiğit et al.^[11] compared TRA and TFA in a randomized clinical trial in 2006. Our results were in concordance with their findings on complication rates and the length of hospital stay; however, they reported a lower success rate and a longer procedural time with TRA, and the number of coronary catheters used did not differ in the two groups. In our study, no significant difference was found between the two groups with regard to success rate and procedural time, and the number of catheters used was significantly lower in the TRA group. Our findings were comparable with similar studies in the literature.^[6,12,13]

In this study, we especially used a single catheter to cannulate both coronary arteries during transradial angiography to shorten the procedure and radiation times (Fig. 1). Our catheter was different from the ones used in similar studies. Louvard et al.^[6,13] used Amplatz left catheters to cannulate both coronary arteries and Yiğit et al.^[11] used standard Judkins catheters. The use of a single Optitorque radial catheter costs lower than the use of two catheters for coronary system, and we did not encounter any complications regarding the use of this catheter.

Interestingly, slow flow was more commonly observed in patients undergoing transradial angiography. This might be an incidental finding because we could not find any information on the association between slow flow and TRA. On the other hand, it may be associated with an increased vagotonic response caused by TRA or the use of midazolam for sedation before the procedure, which might have resulted in hypotension and slow flow. However, midazolam was also used in the TFA group.

The use of a vasodilating agent such as nitroglycerin or verapamil during TRA has been recommended by several interventional cardiologists to prevent radial spasm.^[14,15] Although we did not use a vasodilating agent we encountered such a problem in only one patient. Our opinion is that radial spasm mainly arises from the number of access attempts, and that the best measure to prevent the occurrence of radial spasms is to accomplish TRA with the least number of access attempts.

The major limitation of our study was that it was not a randomized trial and the eligibility of the patients for TRA was determined by the physician, in which circumstance a selection bias might be possible.

In conclusion, transradial coronary angiography may be safely and effectively performed in our country in eligible patients after completing the long learning curve. It is a good alternative to TFA because of lower complication rates and shortened hospital stay.

REFERENCES

1. Lotan C, Hasin Y, Mosseri M, Rozenman Y, Admon D, Nassar H, et al. Transradial approach for coronary angiography and angioplasty. *Am J Cardiol* 1995;76:164-7.
2. Agostoni P, Biondi-Zoccai GG, de Benedictis ML, Rigattieri S, Turri M, Anselmi M, et al. Radial versus femoral approach for percutaneous coronary diagnostic and interventional procedures; Systematic overview and meta-analysis of randomized trials. *J Am Coll Cardiol* 2004;44:349-56.
3. Kiemeneij F, Laarman GJ. Transradial artery Palmaz-Schatz coronary stent implantation: results of a single-center feasibility study. *Am Heart J* 1995;130:14-21.
4. Mann JT 3rd, Arrowood M, Cubeddu G. PTCA using the right radial artery access site. *J Invasive Cardiol* 1995;7:142-7.
5. Wu CJ, Lo PH, Chang KC, Fu M, Lau KW, Hung JS. Transradial coronary angiography and angioplasty in Chinese patients. *Cathet Cardiovasc Diagn* 1997;40:159-63.
6. Louvard Y, Lefevre T, Allain A, Morice M. Coronary angiography through the radial or the femoral approach: The CARAFE study. *Catheter Cardiovasc Interv* 2001;52:181-7.
7. Saito S, Miyake S, Hosokawa G, Tanaka S, Kawamitsu K, Kaneda H, et al. Transradial coronary intervention in Japanese patients. *Catheter Cardiovasc Interv* 1999;46:37-41.
8. Choussat R, Black A, Bossi I, Fajadet J, Marco J. Vascular complications and clinical outcome after coronary angioplasty with platelet IIb/IIIa receptor blockade. Comparison of transradial vs transfemoral arterial access. *Eur Heart J* 2000;21:662-7.
9. Barbeau GR, Arsenault F, Dugas L, Simard S, Lariviere MM. Evaluation of the ulnopalmar arterial arches with pulse oximetry and plethysmography: comparison with the Allen's test in 1010 patients. *Am Heart J* 2004;147:489-93.
10. Louvard Y, Lefevre T, Morice MC. Radial approach: what about the learning curve? *Cathet Cardiovasc Diagn* 1997;42:467-8.
11. Yigit F, Sezgin AT, Erol T, Demircan S, Tekin G, Katircibasi T, et al. An experience on radial versus femoral approach for diagnostic coronary angiography in Turkey. *Anadolu Kardiyol Derg* 2006;6:229-34.
12. Spaulding C, Lefevre T, Funck F, Thebault B, Chauveau M, Ben Hamda K, et al. Left radial approach for coronary angiography: results of a prospective study. *Cathet*

- Cardiovasc Diagn 1996;39:365-70.
13. Louvard Y, Krol M, Pezzano M, Sheers L, Piechaud JF, Marien C, et al. Feasibility of routine transradial coronary angiography: a single operator's experience. *J Invasive Cardiol* 1999;11:543-8.
 14. Coppola J, Patel T, Kwan T, Sanghvi K, Srivastava S, Shah S, et al. Nitroglycerin, nitroprusside, or both, in preventing radial artery spasm during transradial artery catheterization. *J Invasive Cardiol* 2006;18:155-8.
 15. Kiemeneij F, Vajifdar BU, Eccleshall SC, Laarman G, Slagboom T, van der Wieken R. Evaluation of a spasmolytic cocktail to prevent radial artery spasm during coronary procedures. *Catheter Cardiovasc Interv* 2003;58:281-4.